

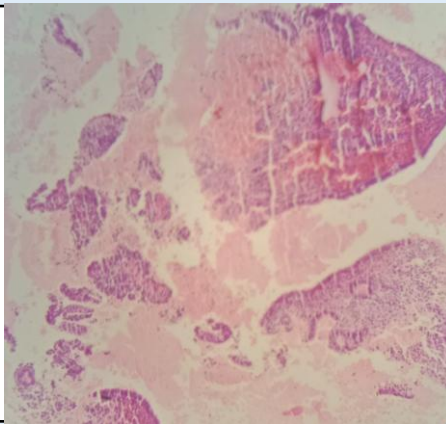
<b>Patient Name</b>	Mrs. SAROJ	<b>Client Name</b>	Civil Hospital Sec-10	<b>Specimen Received</b>	28/02/2019
<b>Age/Sex</b>	27Years/Female			<b>Specimen Type</b>	Tissue
<b>Patient ID</b>	011902280121			<b>Collection Date</b>	28/02/2019
<b>Specimen ID</b>	MOLQ/B-311/19			<b>Report Date</b>	04/03/2019

## SURGICAL PATHOLOGY REPORT

### Endometrium

#### DIAGNOSIS

**Proliferative phase**



#### SPECIMEN

Endometrium

#### GROSS

Received multiple greyish white tissue piece.

#### Microscopy

Section examined shows small endometrial glands with columnar epithelial lining with round to oval nucleus stroma shows mono nuclear inflammatory cells. No granuloma and no malignant cells seen.

**Note :** All biopsy specimen will be stored for 15 (fifteen) days, block and slides for 5 (five) years only from the time of receipt at the laboratory. No request ,for any of the above will be entertained after the due date.

#### Reference

- i) Rosai and Ackerman's Surgical Pathology.
- ii) Modern Surgical Pathology.

**Gulshan Yadav, MD**  
Consultant Pathologist