

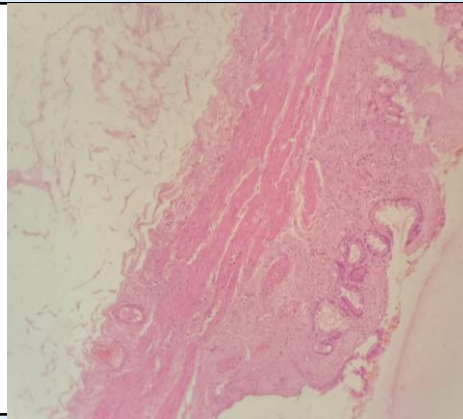
Patient Name	Mrs. CHOTI DEVI	Client Name	Life Care Path Lab, Tauru	Specimen Received	26/02/2019
Age/Sex	35 Years/Female			Specimen Type	Tissue
Patient ID	011902260207			Collection Date	26/02/2019
Specimen ID	MOLQ/B-295/19			Report Date	04/03/2019

SURGICAL PATHOLOGY REPORT

GALL BLADDER.

DIAGNOSIS

CHOLECYSTITIS



SPECIMEN

Gall Bladder.

GROSS

Received 6.5x2.9cm long gall bladder without stones.


Microscopy

1. Section examined shows ulcerative mucosa and Rokitansky Aschoff sinuses (irregularly shaped tubular structures lined by cuboidal lining epithelium with round to oval nucleus) with fibro collagenous tissue and inflammatory cells (lymphocytes).

Note : All biopsy specimen will be stored for 15 (fifteen) days, block and slides for 5 (five) years only from the time of receipt at the laboratory. No request, for any of the above, will be entertained after the due date.

Reference

- i) Rosai and Ackerman's Surgical Pathology.
- ii) Modern Surgical Pathology.



Gulshan Yadav, MD
Consultant Pathologist