

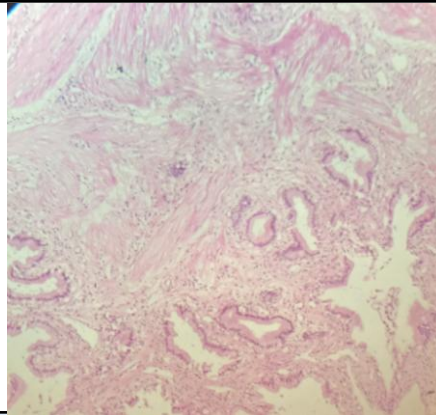
Patient Name	Ms. SHOBHY	Client Name	Uttam Diagnostics, Agra	Specimen Received	27/02/2019
Age/Sex	22 Years/Female			Specimen Type	Tissue
Patient ID	011902270071			Collection Date	27/02/2019
Specimen ID	MOLQ/B-302 /19			Report Date	01/03/2019

SURGICAL PATHOLOGY REPORT

GALL BLADDER.

DIAGNOSIS

CHOLECYSTITIS WITH CHOLELITHIASIS



SPECIMEN

Gall Bladder.

GROSS

Received 6x2.8cm long gall bladder with stone.

Microscopy

- Section examined shows ulcerative mucosa and Rokitansky-Aschoff sinuses (irregularly shaped tubular structures lined by cuboidal lining epithelium with round to oval nucleus) with fibrocollagenous tissue and inflammatory cells (lymphocytes).

Note : All biopsy specimen will be stored for 15 (fifteen) days, block and slides for 5 (five) years only from the time of receipt at the laboratory. No request, for any of the above, will be entertained after the due date.

Reference

- Rosai and Ackerman's Surgical Pathology.
- Modern Surgical Pathology.

Gulshan Yadav, MD
Consultant Pathologist