

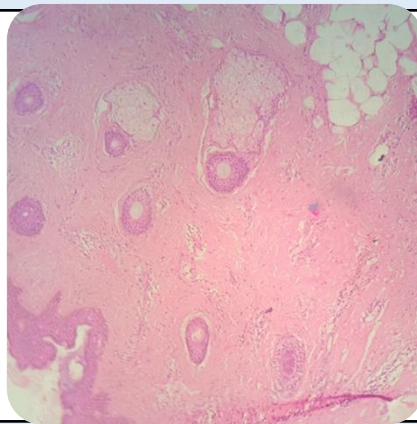
<b>Patient Name</b>	Mrs. URMILA MITTA	<b>Patient Name</b>	Lalita Memorial Hospital Pvt. Ltd. (Rewari)	<b>Specimen Received</b>	24/02/2019
<b>Age/Sex</b>	52 Years/Female			<b>Specimen Type</b>	Tissue
<b>Patient ID</b>	011902240168			<b>Collection Date</b>	24/02/2019
<b>Specimen ID</b>	MOLQ/B-290/19			<b>Report Date</b>	28/02/2019

## SURGICAL PATHOLOGY REPORT

### inclusion cyst

#### DIAGNOSIS

**Inclusion cyst with inflammation.**



#### SPECIMEN

inclusion cyst

#### GROSS

Received 1x1cm greyish white tissue piece.

#### Microscopy

- Section examined shows Squamous lining epithelial with round nucleus. Deeper tissue shows sebaceous glands mature adipose cells, inflammatory cells, fibro collagenous tissue. No granuloma and no malignant cells seen.

**Note :** All biopsy specimen will be stored for 15 (fifteen)days, block and slides for 5(five) years only from the time of receipt at the laboratory. No request ,for any of the above ,will be entertained after the due date.

#### Reference

- Rosai and Ackerman's Surgical Pathology.
- Modern Surgical Pathology.

**Gulshan Yadav, MD  
Consultant Pathologist**