

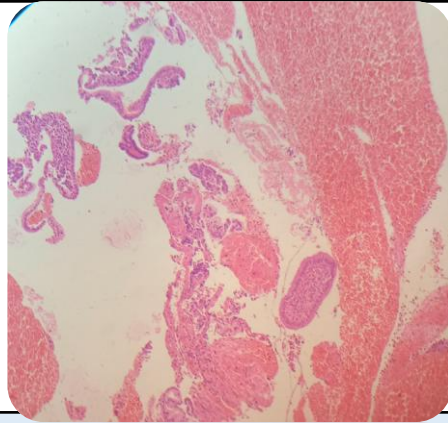
Patient Name	Mrs. ANITA DEVI	Client Name	Lifeaid Wellness Centre	Specimen Received	23/02/2019
Age/Sex	41Years/Female			Specimen Type	Tissue
Patient ID	011902230188			Collection Date	23/02/2019
Specimen ID	MOLQ/B-285/19			Report Date	28/02/2019

SURGICAL PATHOLOGY REPORT

Endometrium

DIAGNOSIS

Disordered proliferative phase.



SPECIMEN

Endometrium

GROSS

Received multiple greyish white tissue piece.

Microscopy

1. Section examined shows small endometrial glands with tortuous glands columnar lining epithelium with small round to oval nucleus with vacuolization with stromal cells and RBCs.

Note : All biopsy specimen will be stored for 15 (fifteen)days, block and slides for 5(five) years only from the time of receipt at the laboratory. No request ,for any of the above ,will be entertained after the due date.

Reference

- i) Rosai and Ackerman's Surgical Pathology.
- ii) Modern Surgical Pathology.

Gulshan Yadav, MD
Consultant Pathologist