

Patient Name	Mrs. POONAM	Client Name	Lucky Lab, Kapriwas	Specimen Received	21/02/2019
Age/Sex	26 Years/Female	Client Code	MOLQ1038P	Specimen Type	Tissue
Patient ID	011902210187	Ref. Doctor		Collection Date	21/02/2019
Specimen ID	MOLQ/B-275/19			Report Date	26/02/2019

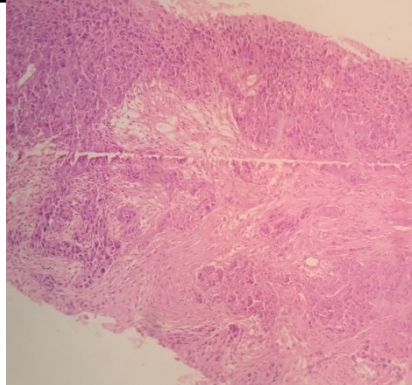
SURGICAL PATHOLOGY REPORT

Breast tissue

DIAGNOSIS

DYSPLASTIC BREAST LESION (SUSPICIOUS OF MALIGNANT CHANGES)

ADVICE: Mammography co-relation.



SPECIMEN

Breast tissue

GROSS

Received one wax block.

Microscopy

1. Section examined shows atypical ductal cells with round to oval nucleus with irregular margins and anisonucleosis surrounded by fibro collagenous tissue.
2. Section also shows mitotic figures.

Note : All biopsy specimen will be stored for 15 (fifteen)days, block and slides for 5(five) years only from the time of receipt at the laboratory. No request ,for any of the above ,will be entertained after the due date.

Reference

- i) Rosai and Ackerman's Surgical Pathology.
- ii) Modern Surgical Pathology.

**Gulshan Yadav, MD
Consultant Pathologist**