

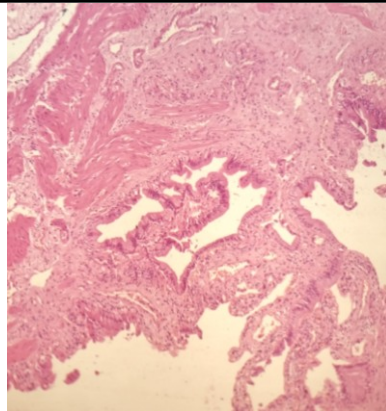
Patient Name	Mr. BASHIR AHMAD	Client Name	New Unique Diagnostic Center,	Specimen Received	22/02/2019
	DAR (I.K)		Jammu & Kashmir	Specimen Type	Tissue
Age/Sex	53 Years/Male	Client Code:	MolQ1833P	Collection Date	22/02/2019
Patient ID	011902220381	Ref. Doc	LIFE LINE LAB SUMBAL	Report Date	25/02/2019
Specimen ID	MOLQ/B-281/19				

SURGICAL PATHOLOGY REPORT

GALL BLADDER.

DIAGNOSIS

CHOLECYSTITIS WITH CHOLELITHIASIS



SPECIMEN

Gall Bladder.

GROSS

Received 9x3.5cm long gall bladder with stones.

Microscopy

- Section examined shows ulcerative mucosa and Rokitansky-Aschoff sinuses (irregularly shaped tubular structures lined by cuboidal lining epithelium with round to oval nucleus) with fibro collagenous tissue and inflammatory cells (lymphocytes).

Note : All biopsy specimen will be stored for 15 (fifteen) days, block and slides for 5 (five) years only from the time of receipt at the laboratory. No request, for any of the above, will be entertained after the due date.

Reference

- Rosai and Ackerman's Surgical Pathology.
- Modern Surgical Pathology.

Gulshan Yadav, MD
Consultant Pathologist