

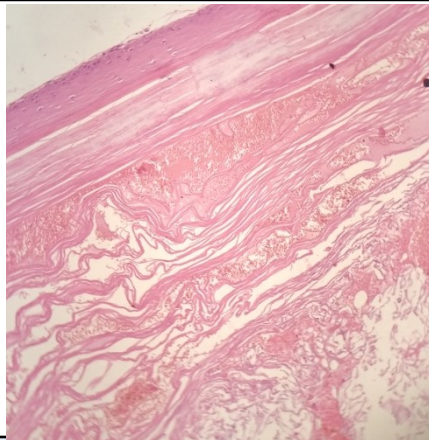
<b>Patient Name</b>	<b>Mrs. NISHA</b>	<b>Client Name</b>	Asian Diagnostic Centre	<b>Specimen Received</b>	22/02/2019
<b>Age/Sex</b>	28 Years/Female	<b>Client Code</b>	MolQ1300CW	<b>Specimen Type</b>	Tissue
<b>Patient ID</b>	011902220289	<b>Ref. Doctor</b>		<b>Collection Date</b>	22/02/2019
<b>Specimen ID</b>	MOLQ/B-278/19			<b>Report Date</b>	25/02/2019

## SURGICAL PATHOLOGY REPORT

Sebaceous cyst

### DIAGNOSIS

**Sebaceous cyst**



#### SPECIMEN

Sebaceous cyst

#### GROSS

Received multiple greyish white tissue piece.

#### Microscopy

1. Section examined shows squamous epithelial lining epithelial with round nucleus and hyperkeratosis and Para keratosis.
2. Deeper tissue shows fibro collagenous tissue and few inflammatory cells.
3. No granuloma and no malignant cells seen.

**Note :** All biopsy specimen will be stored for 15 (fifteen)days, block and slides for 5(five) years only from the time of receipt at the laboratory. No request ,for any of the above ,will be entertained after the due date.

#### Reference

- i) Rosai and Ackerman's Surgical Pathology.
- ii) Modern Surgical Pathology.

**Gulshan Yadav, MD**  
**Consultant Pathologist**