

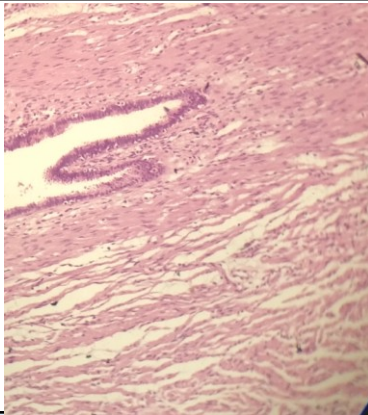
Patient Name	Mrs. RENU	Client Name	Path Star Diagnostic	Specimen Received	21/02/2019
Age/Sex	24Years/Female	Client Code		Specimen Type	Tissue
Patient ID	011902210224	Ref. Doctor		Collection Date	21/02/2019
Specimen ID	MOLQ/B-274/19(2)			Report Date	25/02/2019

SURGICAL PATHOLOGY REPORT

Left fallopian tube

DIAGNOSIS

TUBE CONFIRMED AND UNREMARKABLE.



SPECIMEN

Left fallopian tube

GROSS

Received 2x0.5cm greyish white tissue piece.

Microscopy

- Section examined shows ulcerative mucosa and rokitansky aschoff sinus (irregularly shaped tubular structures lined by cuboidal lining epithelium with round to oval nucleus) with fibro collagenous tissue and inflammatory cells (lymphocytes).

Note : All biopsy specimen will be stored for 15 (fifteen)days, block and slides for 5(five) years only from the time of receipt at the laboratory. No request ,for any of the above ,will be entertained after the due date.

Reference

- Rosai and Ackerman's Surgical Pathology.
- Modern Surgical Pathology.

Gulshan Yadav, MD
Consultant Pathologist