

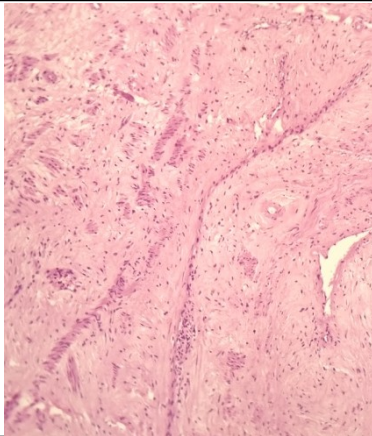
<b>Patient Name</b>	<b>Mr. GOURAV</b>	<b>Client Name</b>	Anil Lab	<b>Specimen Received</b>	17/02/2019
<b>Age/Sex</b>	25 Years/Male	<b>Client Code:</b>	MOLQ1005P	<b>Specimen Type</b>	Tissue
<b>Patient ID</b>	011902170247			<b>Collection Date</b>	17/02/2019
<b>Specimen ID</b>	MOLQ/B-254/19			<b>Report Date</b>	20/02/2019

## SURGICAL PATHOLOGY REPORT

Cervical Swelling

### DIAGNOSIS

**Infective Cystic Lesion**



#### SPECIMEN

Cervical Swelling

#### GROSS

Received 2x1cm greyish white tissue piece with skin.

#### Microscopy

- Section examined shows Squamous lining epithelium with mild hyperkeratosis. Deeper tissue shows fibro collagenous tissue, blood vessels sebaceous glands and inflammatory cells (polymorphs, lymphocytes. No granuloma and no malignant cells seen.

**Note :** All biopsy specimen will be stored for 15 (fifteen)days, block and slides for 5(five) years only from the time of receipt at the laboratory. No request ,for any of the above ,will be entertained after the due date.

#### Reference

- Rosai and Ackerman's Surgical Pathology.
- Modern Surgical Pathology. *Report generated at MolQ Laboratory, Gurgaon*

**Gulshan Yadav, MD**  
**Consultant Pathologist**