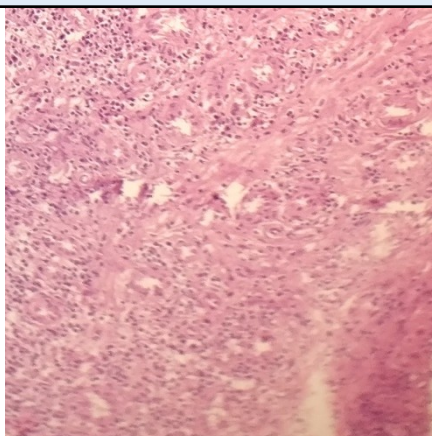


Patient Name	Mrs. JARINA	Client Name	Arban Hospital	Specimen Received	16/02/2019
Age/Sex	30 Years/Female	Client Code	MolQ1684P	Specimen Type	Tissue
Patient ID	011902160161			Collection Date	16/02/2019
Specimen ID	MOLQ/B-252/19			Report Date	20/02/2019

SURGICAL PATHOLOGY REPORT

L4-L5 Spondylitis

Kindly correlate clinically and radiologically



SPECIMEN

L4-L5 Spondylitis

GROSS

Received multiple greyish white tissue piece.

Microscopy

1. Section examined shows fibro collagenous tissue, muscle bundles, mature adipose cells, blood vessels with inflammatory cells (polymorphs and lymphocytes).
2. No malignant and no granuloma seen.

Note : All biopsy specimen will be stored for 15 (fifteen) days, block and slides for 5 (five) years only from the time of receipt at the laboratory. No request for any of the above, will be entertained after the due date.

Reference

- i) Rosai and Ackerman's Surgical Pathology.
- ii) Modern Surgical Pathology.

**Gulshan Yadav, MD
Consultant Pathologist**