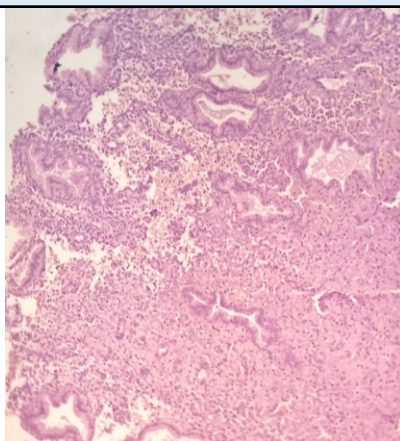


<b>Patient Name</b>	<b>Mrs. SUDESH</b>	<b>Client Name</b>	Path Star Diagnostic	<b>Specimen Received</b>	16/02/2019
<b>Age/Sex</b>	48 Years/Female	<b>Client Code</b>	MOLQ1098CM	<b>Specimen Type</b>	Tissue
<b>Patient ID</b>	011902160154			<b>Collection Date</b>	16/02/2019
<b>Specimen ID</b>	MOLQ/B-251/19			<b>Report Date</b>	20/02/2019

## SURGICAL PATHOLOGY REPORT

### ENDOMETRIUM

**Proliferative Phase.**



#### **SPECIMEN**

Endometrium

#### **GROSS**

Received multiple greyish white tissue piece.

#### **Microscopy**

- Section examined shows small endometrial glands having cuboidal lining epithelium stroma shows mononuclear inflammatory cells and RBCs.

No granuloma and no malignant cells seen.

**Note :** All biopsy specimen will be stored for 15 (fifteen) days, block and slides for 5 (five) years only from the time of receipt at the laboratory. No request for any of the above, will be entertained after the due date.

#### **Reference**

- Rosai and Ackerman's Surgical Pathology.
- Modern Surgical Pathology.

**Gulshan Yadav, MD**  
Consultant Pathologist