

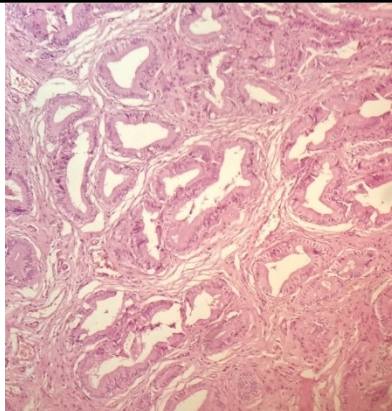
Patient Name	Mrs. FEHMEEEDA 7633	Client Name	Patients Care Clinical	Specimen Received	15/02/2019
Age/Sex	38 Years/Female		Laboratory, Jammu & Kashmir	Specimen Type	Tissue
Patient ID	011902150371	Client Code	MolQ1839P	Collection Date	15/02/2019
Specimen ID	MOLQ/B-245/19	Ref. Doctor		Report Date	18/02/2019

SURGICAL PATHOLOGY REPORT

GALL BLADDER.

DIAGNOSIS

CHOLECYSTITIS WITH CHOLELITHIASIS



SPECIMEN

Gall Bladder.

GROSS

Received 6.7x3.2cm long gall bladder. Cut section shows stones.

Microscopy

- Section examined shows ulcerative mucosa and Rokitansky-Aschoff sinuses (irregularly shaped tubular structures lined by cuboidal lining epithelium with round to oval nucleus) with fibro collagenous tissue and inflammatory cells (lymphocytes).

Note : All biopsy specimen will be stored for 15 (fifteen) days, block and slides for 5 (five) years only from the time of receipt at the laboratory. No request, for any of the above, will be entertained after the due date.

Reference

- Rosai and Ackerman's Surgical Pathology.
- Modern Surgical Pathology.

Gulshan Yadav, MD
Consultant Pathologist