

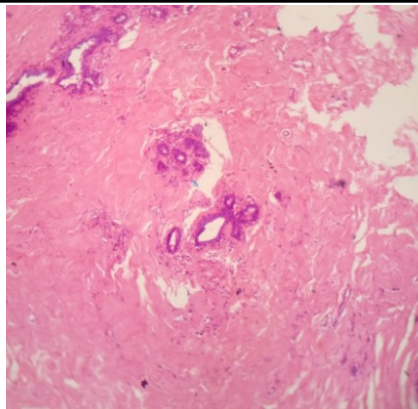
<b>Patient Name</b>	<b>Mr. SONU CHOUHAN</b>	<b>Client Name</b>	SKD Memorials Sahara Hospital	<b>Specimen Received</b>	15/02/2019
<b>Age/Sex</b>	30 Years/male			<b>Specimen Type</b>	Tissue
<b>Patient ID</b>	011902150249	<b>Client Code</b>	MolQ1831P	<b>Collection Date</b>	15/02/2019
<b>Specimen ID</b>	MOLQ/B-243/19 (2)	<b>Ref. Doctor</b>		<b>Report Date</b>	18/02/2019

## SURGICAL PATHOLOGY REPORT

### Left Breast

#### DIAGNOSIS

**Gynecomastia**



#### SPECIMEN

Left breast

#### GROSS

Received 5x5cm greyish white tissue piece.

#### Microscopy

- Section examined shows ductal cells with cuboidal lining epithelium with small round nucleus surrounded by fibro collagenous tissue.  
No granuloma and no malignant cells seen.

**Note :** All biopsy specimen will be stored for 15 (fifteen)days, block and slides for 5(five) years only from the time of receipt at the laboratory. No request ,for any of the above ,will be entertained after the due date.

#### Reference

- Rosai and Ackerman's Surgical Pathology.
- Modern Surgical Pathology.

**Gulshan Yadav, MD  
Consultant Pathologist**