

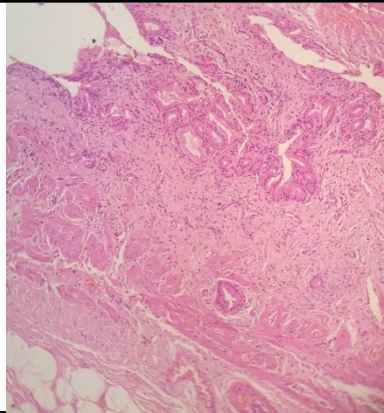
Patient Name	Mrs. MAMTA	Client Name	Rathore Hospital	Specimen Received	15/02/2019
Age/Sex	23 Years/Female			Specimen Type	Tissue
Patient ID	011902150150	Client Code	MolQ1856P	Collection Date	15/02/2019
Specimen ID	MOLQ/B-242/19 (1)	Ref. Doctor		Report Date	18/02/2019

SURGICAL PATHOLOGY REPORT

GALL BLADDER.

DIAGNOSIS

CHOLECYSTITIS WITH CHOLELITHIASIS



SPECIMEN

Gall Bladder.

GROSS

Received 6.1x2.2cm long gall bladder. Cut section shows stones

Microscopy

1. Section examined shows ulcerative mucosa and Rokitansky-Aschoff sinuses (irregularly shaped tubular structures lined by cuboidal lining epithelium with round to oval nucleus) with fibrocollagenous tissue and inflammatory cells (lymphocytes).

Note : All biopsy specimen will be stored for 15 (fifteen) days, block and slides for 5 (five) years only from the time of receipt at the laboratory. No request, for any of the above, will be entertained after the due date.

Reference

- i) Rosai and Ackerman's Surgical Pathology.
- ii) Modern Surgical Pathology.

**Gulshan Yadav, MD
Consultant Pathologist**