

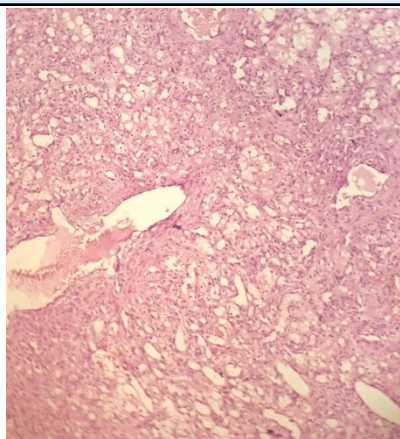
Patient Name	Master. KRISHAN	Client Name	MolQ Staff	Specimen Received	15/02/2019
Age/Sex	07 Years/male			Specimen Type	Tissue
Patient ID	011902150012			Collection Date	15/02/2019
Specimen ID	MOLQ/B-239/19			Report Date	16/02/2019

SURGICAL PATHOLOGY REPORT

Eyelid Papilloma

BENIGN MESENCHYMAL LESION

Kindly correlate clinically.



SPECIMEN

Eyelid Papilloma

GROSS

Received 1x1cm greyish white tissue piece.

Microscopy

1. Section examined shows squamous lining epithelium having round nucleus, deeper tissues shows fibro-collagenous tissue, blood vessels and inflammatory cells.
2. No koilocytic changes and no atypia seen.
3. No malignant cells and no granuloma seen.

Note : All biopsy specimen will be stored for 15 (fifteen) days, block and slides for 5 (five) years only from the time of receipt at the laboratory. No request for any of the above, will be entertained after the due date.

Reference

- i) Rosai and Ackerman's Surgical Pathology.
- ii) Modern Surgical Pathology.

Gulshan Yadav, MD
Consultant Pathologist