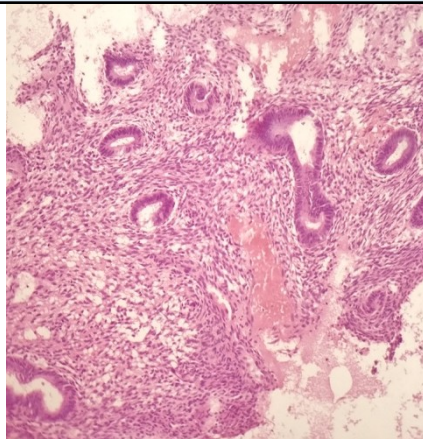


Patient Name	Mrs. RITA PAL	Client Name	Civil Hospital Sec-10	Specimen Received	14/02/2019
Age/Sex	30 Years/Female		Gurgaon	Specimen Type	Tissue
Patient ID	011902140342			Collection Date	14/02/2019
Specimen ID	MOLQ/B-238/19			Report Date	16/02/2019

SURGICAL PATHOLOGY REPORT

ENDOMETRIUM

PROLIFERATIVE PHASE



SPECIMEN

Endometrium

GROSS

Received multiple greyish white tissue piece.

Microscopy

1. Section examined shows small endometrium glands with columnar lining epithelium with round nucleus. Stroma shows mononuclear inflammatory cells.
2. No malignant cells and no granuloma seen.

Note : All biopsy specimen will be stored for 15 (fifteen) days, block and slides for 5 (five) years only from the time of receipt at the laboratory. No request for any of the above, will be entertained after the due date.

Reference

- i) Rosai and Ackerman's Surgical Pathology.
- ii) Modern Surgical Pathology.

Gulshan Yadav, MD
Consultant Pathologist