

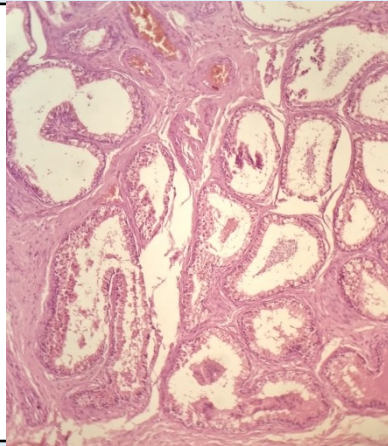
Patient Name	Mr. M ASHRAF MANELWAN	Client Name	Patients Care Clinical Laboratory, J& K	Specimen Received	13/02/2019
Age/Sex	43/M	Client Code:	MolQ1839P	Specimen Type	Tissue
Patient ID	011902120417	Ordering Physician	ARFAT CLI LAB	Collection Date	13/02/2019
Specimen ID	MOLO/B-234/19			Report Date	16/02/2019

SURGICAL PATHOLOGY REPORT

Right testicular swelling.

DIAGNOSIS

Partial atrophic testes.



SPECIMEN

Right testicular swelling.

GROSS

Received 1x1cm greyish white tissue piece.

Microscopy

1. Section examined shows seminiferous tubules with immature mature spermatogenic cells with thick basement membrane in few seminiferous tubules surrounding supporting cells.
2. No granuloma and no malignant cells seen.

Note : All biopsy specimen will be stored for 15 (fifteen)days, block and slides for 5(five) years only from the time of receipt at the laboratory. No request ,for any of the above ,will be entertained after the due date.

Reference

- i) Rosai and Ackerman's Surgical Pathology.
- ii) Modern Surgical Pathology.

**Gulshan Yadav, MD
Consultant Pathologist**