

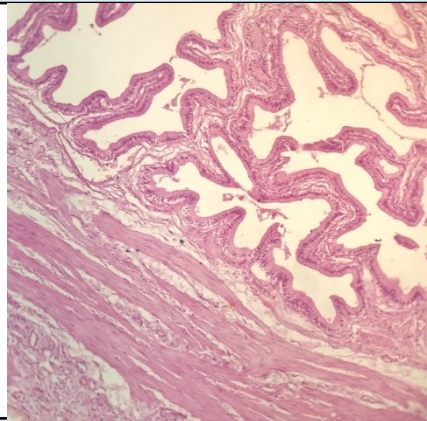
<b>Patient Name</b>	<b>Mrs. RAZIA BANU</b>	<b>Client Name</b>	New Unique Diagnostic Center	<b>Specimen Received</b>	13/02/2019
<b>Age/Sex</b>	28YRS/F		Jammu & Kashmir	<b>Specimen Type</b>	Tissue
<b>Patient ID</b>	011902120394	<b>Client Code:</b>	MolQ1833P	<b>Collection Date</b>	13/02/2019
<b>Specimen ID</b>	MOLQ/B-233/19	<b>Ordering Physician</b>	HEALTH CREASANT	<b>Report Date</b>	16/02/2019

## SURGICAL PATHOLOGY REPORT

### GALL BLADDER.

#### DIAGNOSIS

#### CHOLECYSTITIS



#### SPECIMEN

Gall Bladder.

#### GROSS

Received 6.7X3.2cm long gall bladder. Cut section shows no stone.

#### Microscopy

- Section examined shows ulcerative mucosa and Rokitansky-Aschoff sinuses (irregularly shaped tubular structures lined by cuboidal lining epithelium with round to oval nucleus) with fibrocollagenous tissue and inflammatory cells (lymphocytes).

**Note :** All biopsy specimen will be stored for 15 (fifteen) days, block and slides for 5 (five) years only from the time of receipt at the laboratory. No request for any of the above will be entertained after the due date.

#### Reference

- Rosai and Ackerman's Surgical Pathology.
- Modern Surgical Pathology.

**Gulshan Yadav, MD**  
Consultant Pathologist