

<b>Patient Name</b>	<b>Ms. FALAQ JAN R / Client Name</b>	Patients Care Clinical Laboratory, Jammu & Kashmir	<b>Specimen Received</b>	12-Feb-2019
<b>Age/Sex</b>	22/F	<b>Client Code</b>	<b>Specimen Type</b>	Tissue
<b>Patient ID</b>	011902030190	<b>Ref. Doctor</b>	<b>Collection Date</b>	12-Feb-2019
<b>Specimen ID</b>	MOLQ/B-191-19	CARE CLI LAB DOORU	<b>Report Date</b>	14-Feb-2019

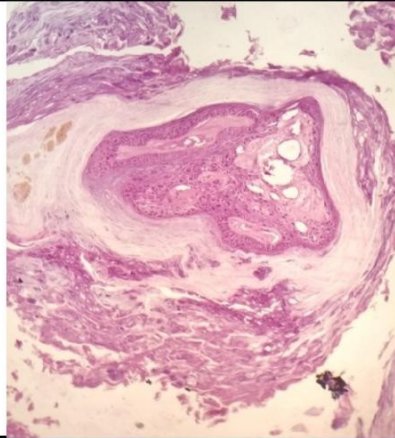
## SURGICAL PATHOLOGY REPORT

(?)

### DIAGNOSIS

#### IMPRESSION

**Hyperkeratotic lesion  
(Suspected Viral Etiology)**



#### SPECIMEN

(?)

#### GROSS

Received 1x1cm greyish white tissue piece.

#### Microscopy

1. Section examined shows Squamous lining epithelial with mild nuclear atypia, marked hyperkeratosis, parakeratosis and spongiosis.
2. Deeper tissue shows fibro collagenous tissue, blood vessels.

**Note :** All biopsy specimen will be stored for 15 (fifteen)days, block and slides for 5(five) years only from the time of receipt at the laboratory. No request ,for any of the above ,will be entertained after the due date.

#### Reference

- i) Rosai and Ackerman's Surgical Pathology.
- ii) Modern Surgical Pathology.

**Gulshan Yadav, MD  
Consultant Pathologist**