

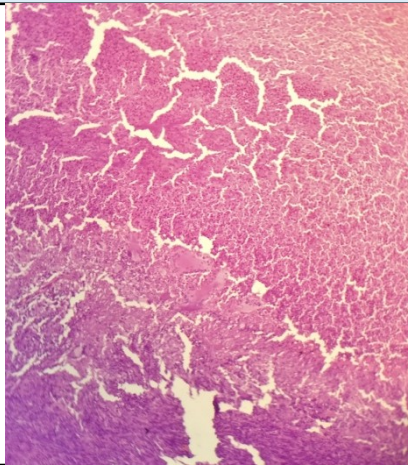
Patient Name	Mr. RISABH	Client Name	Civil Hospital-P, Gurgaon	Specimen Received	11-Feb-2019
Age/Sex	21 YEARS/MALE	Client Code	MolQ1681P	Specimen Type	Tissue
Patient ID	011902110181	Ref. Doctor	DR.SAURABH DESWAL	Collection Date	11-Feb-2019
Specimen ID	MOLQ/B-224-19			Report Date	13-Feb-2019

SURGICAL PATHOLOGY REPORT

Right Cheek

DIAGNOSIS

PARASITIC INFESTATION (GRANULOMATOUS REACTION)



SPECIMEN

Right Cheek

GROSSING

Received 1x1cm greyish white tissue piece, firm in consistency, regular borders and margins.

Microscopy

- Section examined shows fibrocollagenous tissue, necrosis surrounded by multinucleated giant cells, muscle bundles, inflammatory cells (lymphocytes and lipid laden macrophages) and tissue eosinophilia.
- No malignant cells seen.

Note : All biopsy specimen will be stored for 15 (fifteen) days, block and slides for 5 (five) years only from the time of receipt at the laboratory. No request for any of the above will be entertained after the due date.

Reference

- Rosai and Ackerman's Surgical Pathology.
- Modern Surgical Pathology
- Shafers, 7th Edition
- Cawson, Oral Diseases
- Neville, 3rd Edition

Tina Bhardwaj, MDS
Consultant Oral Histopathologist

Gulshan Yadav, MD
Consultant Pathologist