

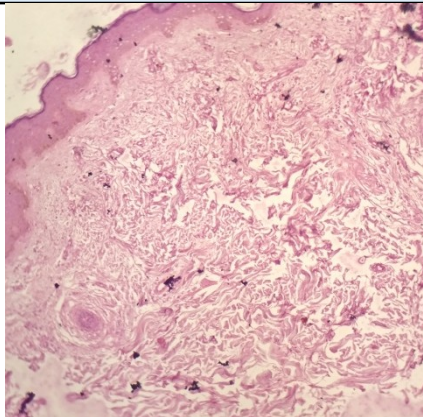
<b>Patient Name</b>	Mr. VIVEKANAND	<b>Client Name</b>	Civil Hospital-P	<b>Specimen Received</b>	11-Feb-2019
<b>Age/Sex</b>	35/M		Gurgaon	<b>Specimen Type</b>	Tissue
<b>Patient ID</b>	011902110176	<b>Client Code</b>	MolQ1681P	<b>Collection Date</b>	11-Feb-2019
<b>Specimen ID</b>	MOLQ/B-225/19	<b>Ref. Doc</b>	DR.SOURABH DESWAL	<b>Report Date</b>	13-Feb-2019

## SURGICAL PATHOLOGY REPORT

### Sebaceous Cyst (Back)

#### DIAGNOSIS

### SEBACEOUS CYST



#### SPECIMEN

Sebaceous Cyst (Back)

#### GROSS

Received 6x2.8 cm greyish white tissue piece. Cut section shows necrotic material.

#### Microscopy

1. Section examined shows squamous epithelial lining with round to oval nucleus, keratin flakes, fibro collagenous tissue and blood vessels.
2. No malignant cells and no granuloma seen.

**Note :** All biopsy specimen will be stored for 15 (fifteen) days, block and slides for 5 (five) years only from the time of receipt at the laboratory. No request ,for any of the above will be entertained after the due date.

#### Reference

- i) Rosai and Ackerman's Surgical Pathology.
- ii) Modern Surgical Pathology.

**Gulshan Yadav, MD**  
Consultant Pathologist