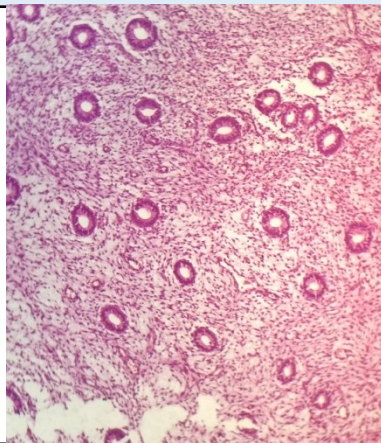


Patient Name	Mrs. SHASHI JAIN	Client Name	SBS Diagnostic Centre,	Specimen Received	10-Feb-2019
Age/Sex	37/F		Gurgaon	Specimen Type	Tissue
Patient ID	011902100013	Client Code	MolQ1325CM	Collection Date	10-Feb-2019
Specimen ID	MOLQ/B-219/19	Ref. Doctor		Report Date	13-Feb-2019

SURGICAL PATHOLOGY REPORT

ENDOMETRIUM

PROLIFERATIVE PHASE



SPECIMEN

Endometrium

GROSS

Received multiple greyish white tissue piece.

Microscopy

1. Section examined shows small endometrial glands having cuboidal lining epithelium with small round nucleus.
2. Stroma shows mononuclear inflammatory cells.
3. No malignant cells and no granuloma seen.

Note : All biopsy specimen will be stored for 15 (fifteen) days, block and slides for 5 (five) years only from the time of receipt at the laboratory. No request for any of the above, will be entertained after the due date.

Reference

- i) Rosai and Ackerman's Surgical Pathology.
- ii) Modern Surgical Pathology.

Gulshan Yadav, MD
Consultant Pathologist