

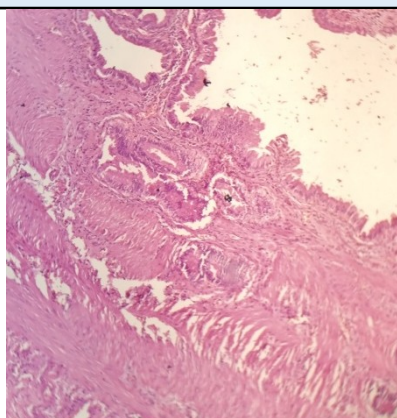
Patient Name	Mrs. HALEEMA 7590	Client Name	Patients Care Clinical Laboratory,	Specimen Received	09-Feb-2019
Age/Sex	60/F		Jammu & Kashmir	Specimen Type	Tissue
Patient ID	011902080329	Client Code	MolQ1839P	Collection Date	09-Feb-2019
Specimen ID	MOLQ/B-212/19	Ref. Doc	LIFE CARE CLI LAB	Report Date	11-Feb-2019

SURGICAL PATHOLOGY REPORT

GALL BLADDER.

DIAGNOSIS

CHOLECYSTITIS



SPECIMEN

Gall Bladder.

GROSS

Received 6.5 x 2.1 cm long gall bladder.

Microscopy

- Section examined shows ulcerative mucosa and Rokitansky-Aschoff sinuses (irregularly shaped tubular structures lined by cuboidal lining epithelium with round to oval nucleus) with fibro collagenous tissue and inflammatory cells (lymphocytes).

Note : All biopsy specimen will be stored for 15 (fifteen) days, block and slides for 5 (five) years only from the time of receipt at the laboratory. No request ,for any of the above will be entertained after the due date.

Reference

- Rosai and Ackerman's Surgical Pathology.
- Modern Surgical Pathology.

Gulshan Yadav, MD
Consultant Pathologist