

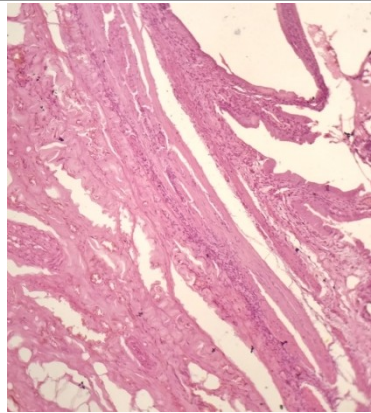
Patient Name	Mrs. RENU	Client Name	Civil Hospital Sec-10, Gurgaon	Specimen Received	08-Feb-2019
Age/Sex	34/F	Client Code	MOLQ1062CM	Specimen Type	Tissue
Patient ID	011902080083	Ref. Doc		Collection Date	08-Feb-2019
Specimen ID	MOLQ/B-204/19			Report Date	12-Feb-2019

SURGICAL PATHOLOGY REPORT

GALL BLADDER.

DIAGNOSIS

CHOLECYSTITIS WITH CHOLELITHIASIS



SPECIMEN

Gall Bladder.

GROSS

Received 6.5 x 2.1 cm long gall bladder. Cut section shows stones.

Microscopy

1. Section examined shows ulcerative mucosa and Rokitansky-Aschoff sinuses (irregularly shaped tubular structures lined by cuboidal lining epithelium with round to oval nucleus) with fibro collagenous tissue and inflammatory cells (lymphocytes).

Note : All biopsy specimen will be stored for 15 (fifteen) days, block and slides for 5 (five) years only from the time of receipt at the laboratory. No request ,for any of the above will be entertained after the due date.

Reference

- i) Rosai and Ackerman's Surgical Pathology.
- ii) Modern Surgical Pathology.

Gulshan Yadav, MD
Consultant Pathologist