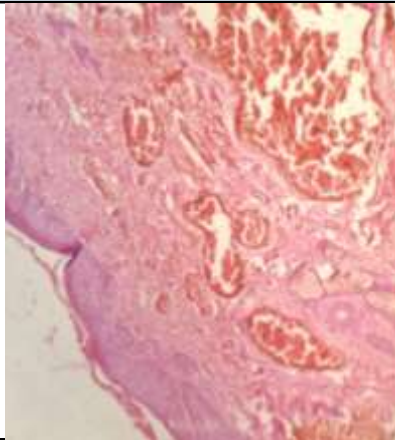


<b>Patient Name</b>	Mrs. SHAGUFTA	<b>Client Name</b>	New Unique Diagnostic Center,	<b>Specimen Received</b>	09-Feb-2019
<b>Age/Sex</b>	/F		Jammu & Kashmir	<b>Specimen Type</b>	Tissue
<b>Patient ID</b>	011902080375	<b>Client Code</b>	MolQ1833P	<b>Collection Date</b>	09-Feb-2019
<b>Specimen ID</b>	MOLQ/B-213-19	<b>Ref. Doctor</b>	BILAL LAB SUMBAL	<b>Report Date</b>	11-Feb-2019

**SURGICAL PATHOLOGY REPORT**  
**HEMORRHOIDS**

**DIAGNOSIS**

**HEMORRHOIDS**



**SPECIMEN**  
Hemorrhoids

**GROSS**  
Received 2x1cm greyish white tissue piece.

**Microscopy**

1. Section examined shows submucosal glands, fibro collagenous tissue with blood vessels.No granuloma and no malignant cells seen.

**Note :** All biopsy specimen will be stored for 15 (fifteen)days, block and slides for 5(five) years only from the time of receipt at the laboratory. No request ,for any of the above ,will be entertained after the due date.

**Reference**

- i) Rosai and Ackerman's Surgical Pathology.
- ii) Modern Surgical Pathology.

**Gulshan Yadav, MD**  
**Consultant Pathologist**