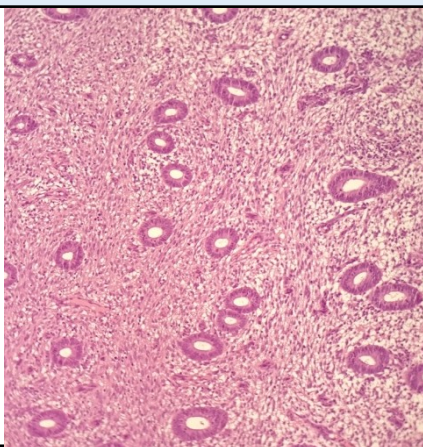


Patient Name	Mrs. NASEEMA	Client Name	Danish Lab,	Specimen Received	05-Feb-2019
Age/Sex	35/F		Jammu & Kashmir	Specimen Type	Tissue
Patient ID	011902050174	Client Code	MolQ1850P	Collection Date	05-Feb-2019
Specimen ID	MOLQ/B-199/19	Ref. Doctor		Report Date	10-Feb-2019

SURGICAL PATHOLOGY REPORT

ENDOMETRIUM

PROLIFERATIVE PHASE



SPECIMEN

Endometrium

GROSS

Received multiple greyish white tissue piece.

Microscopy

1. Section Examined Shows Small Endometrial Glands Having Cuboidal Lining Epithelium With Small Round Nucleus.
2. Stroma Shows Mononuclear Inflammatory Cells
3. No Malignant And No Granuloma Seen.

Note : All biopsy specimen will be stored for 15 (fifteen) days, block and slides for 5 (five) years only from the time of receipt at the laboratory. No request for any of the above, will be entertained after the due date.

Reference

- i) Rosai and Ackerman's Surgical Pathology.
- ii) Modern Surgical Pathology.

Gulshan Yadav, MD
Consultant Pathologist