

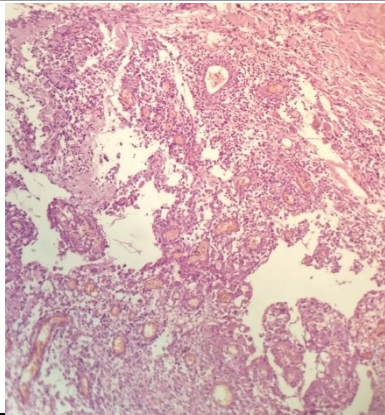
| | | | | | |
|---------------------|---------------|--------------------|---------------------|--------------------------|------------|
| Patient Name | Mrs. MONIKA | Client Name | Brijanand Path Lab, | Specimen Received | 05/02/2019 |
| Age/Sex | 29/F | Client Code | MOLQ1133CM | Specimen Type | Tissue |
| Patient ID | 011902050167 | Ref. Doc | | Collection Date | 05/02/2019 |
| Specimen ID | MOLQ/B-195/19 | | | Report Date | 08/02/2019 |

SURGICAL PATHOLOGY REPORT

Sebaceous cyst

DIAGNOSIS

Infected Benign Cyst



SPECIMEN

Sebaceous cyst

GROSS

Received 1x1cm greyish white tissue piece.

Microscopy

1. Section examined shows fibro collagenous tissue, mature adipose cells with large number of inflammatory cells (lymphocyte).
2. Section also shows macrophages and blood vessels.
3. No granuloma and no malignant cells seen.

Note : All biopsy specimen will be stored for 15 (fifteen) days, block and slides for 5 (five) years only from the time of receipt at the laboratory. No request ,for any of the above will be entertained after the due date.

Reference

- i) Rosai and Ackerman's Surgical Pathology.
- ii) Modern Surgical Pathology.

**Gulshan Yadav, MD
Consultant Pathologist**