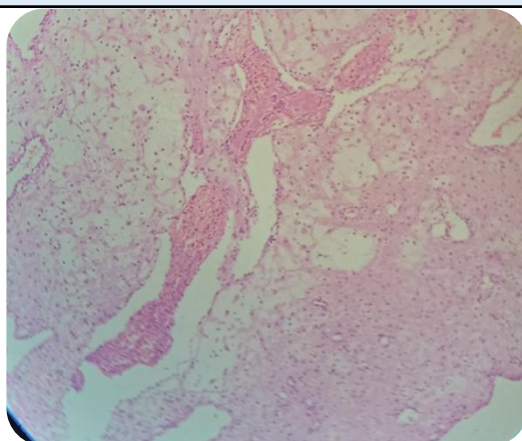


Patient Name	Mrs. MONIKA TOMAR	Client Name	Lifeaid Wellness Centre	Specimen Received	02/02/2019
Age/Sex	33 Years/Female			Specimen Type	Tissue
Patient ID	011902020104			Collection Date	02/02/2019
Specimen ID	MOLQ/B-182/19 (1)			Report Date	06/02/2019

SURGICAL PATHOLOGY REPORT

Endometrium

Hyperprogestronic effect



SPECIMEN
Endometrium

GROSS
Received multiple greyish white tissue piece.

Microscopy

1. Section examined shows decidual cells with endometrial glands having cuboidal epithelium.
2. No granuloma and no malignant cells seen.

Note : All biopsy specimen will be stored for 15 (fifteen) days, block and slides for 5 (five) years only from the time of receipt at the laboratory. No request for any of the above, will be entertained after the due date.

Reference

- i) Rosai and Ackerman's Surgical Pathology.
- ii) Modern Surgical Pathology.

A handwritten signature in black ink, appearing to read 'Gulshan', written over a light blue rectangular background.

Gulshan Yadav, MD
Consultant Pathologist