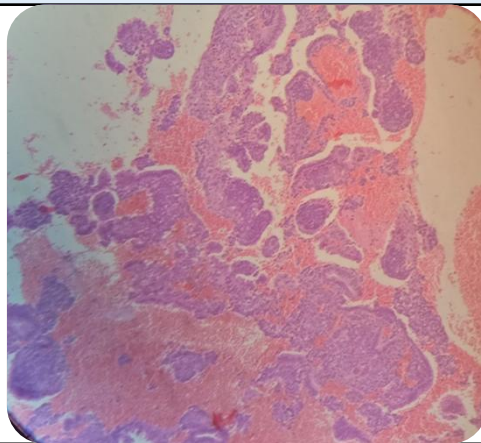


<b>Patient Name</b>	Mrs. SANGEETA	<b>Client Name</b>	Lal Superspeciality Hospital	<b>Specimen Received</b>	02/02/2019
<b>Age/Sex</b>	45 Years/Female			<b>Specimen Type</b>	Tissue
<b>Patient ID</b>	011902020098			<b>Collection Date</b>	02/02/2019
<b>Specimen ID</b>	MOLQ/B-181/19			<b>Report Date</b>	06/02/2019

## SURGICAL PATHOLOGY REPORT

### ENDOMETRIUM

#### Proliferative phase



#### SPECIMEN

Endometrium

#### GROSS

Received multiple greyish white tissue piece.

#### Microscopy

- Section examined shows broken endometrial glands having with round to oval nucleus with ectocervix. Stroma shows mononuclear inflammatory cells.
- No granuloma and no malignant cells seen.

**Note :** All biopsy specimen will be stored for 15 (fifteen) days, block and slides for 5 (five) years only from the time of receipt at the laboratory. No request for any of the above, will be entertained after the due date.

#### Reference

- Rosai and Ackerman's Surgical Pathology.
- Modern Surgical Pathology.

**Gulshan Yadav, MD**  
Consultant Pathologist