

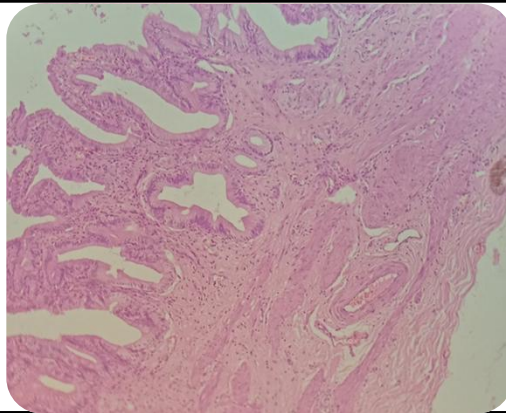
Patient Name	Ms. ARIZOO 7519	Client Name	Patients Care Clinical	Specimen Received	03/02/2019
Age/Sex	19Years/Female		Laboratory, Jammu Kashmir	Specimen Type	Tissue
Patient ID	011902010286	Client Code	MolQ1839P	Collection Date	03/02/2019
Specimen ID	MOLQ/B-183/19			Report Date	06/02/2019

SURGICAL PATHOLOGY REPORT

GALL BLADDER.

DIAGNOSIS

CHOLECYSTITIS WITH CHOLELITHIASIS



SPECIMEN

Gall Bladder.

GROSS

Received 6.2x3.1cm long gall bladder. Cut section shows tiny stones.

Microscopy

- Section examined shows ulcerative mucosa and Rokitansky Aschoff sinus (irregularly shaped tubular structures lined by cuboidal lining epithelium with round to oval nucleus) with fibro collagenous tissue and inflammatory cells (lymphocytes).

Note : All biopsy specimen will be stored for 15 (fifteen) days, block and slides for 5 (five) years only from the time of receipt at the laboratory. No request for any of the above will be entertained after the due date.

Reference

- Rosai and Ackerman's Surgical Pathology.
- Modern Surgical Pathology.

Gulshan Yadav, MD
Consultant Pathologist