

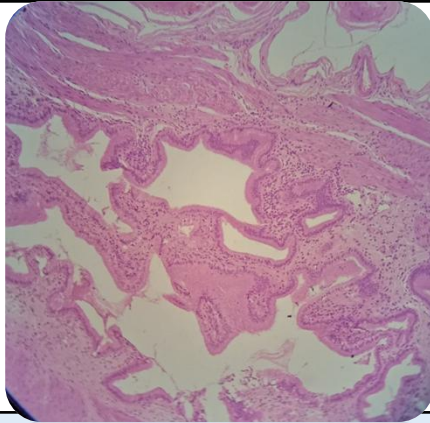
Patient Name	Mrs. YASMEENA MANZOOR	Client Name	Patients Care Clinical Laboratory, Jammu Kashmir	Specimen Received	03/02/2019
Age/Sex	30 Years/Female	Client Code	MolQ1839P	Specimen Type	Tissue
Patient ID	011902010080			Collection Date	03/02/2019
Specimen ID	MOLQ/B-184/19			Report Date	06/02/2019

SURGICAL PATHOLOGY REPORT

GALL BLADDER.

DIAGNOSIS

CHOLECYSTITIS WITH CHOLELITHIASIS



SPECIMEN

Gall Bladder.

GROSS

Received 6.5x2.2cm long gall bladder already cut open without stone.

Microscopy

- Section examined shows ulcerative mucosa and Rokitansky Aschoff sinuses (irregularly shaped tubular structures lined by cuboidal lining epithelium with round to oval nucleus) with fibro collagenous tissue and inflammatory cells (lymphocytes).

Note : All biopsy specimen will be stored for 15 (fifteen) days, block and slides for 5 (five) years only from the time of receipt at the laboratory. No request, for any of the above, will be entertained after the due date.

Reference

- Rosai and Ackerman's Surgical Pathology.
- Modern Surgical Pathology.

**Gulshan Yadav, MD
Consultant Pathologist**