

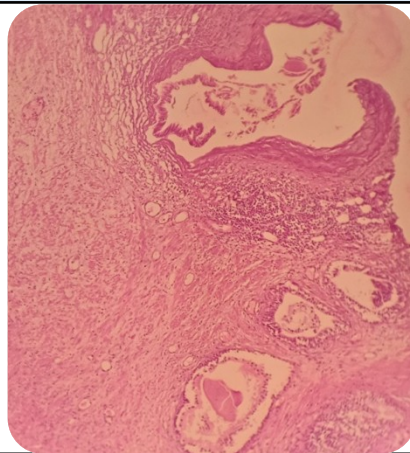
Patient Name	Mr. WALI MOHAMMAD	Client Name	Kamal Hospital and	Specimen Received	31/01/2019
Age/Sex	70/M		Maternity Centre	Specimen Type	Tissue
Patient ID	011901310296	Client Code	MolQ1329CM	Collection Date	31/01/2019
Specimen ID	MOLQ/B-178/19	Ref. Doctor		Report Date	04/02/2019

SURGICAL PATHOLOGY REPORT

TURP

DIAGNOSIS

BENIGN PROSTATIC HYPERPLASIA.



SPECIMEN

TURP

GROSS

Received multiple greyish white tissue piece measuring 4x3cm in aggregate.

Microscopy

- Section examined shows bilayered prostatic glands with columnar lining epithelium and with small round to oval nucleus surrounded by large number of fibrocollagenous tissue and mononuclear inflammatory cell.

Note : All biopsy specimen will be stored for 15 (fifteen)days, block and slides for 5(five) years only from the time of receipt at the laboratory. No request ,for any of the above ,will be entertained after the due date.

Reference

- Rosai and Ackerman's Surgical Pathology.
- Modern Surgical Pathology.

Gulshan Yadav, MD
Consultant Pathologist