

Patient Name	Mrs. POONAM	Client Name	Gobind Hospital	Specimen Received	31/01/2019
Age/Sex	35/M	Ref. Doctor		Specimen Type	Tissue
Patient ID	011901310072			Collection Date	31/01/2019
Specimen ID	MOLQ/B-170/19			Report Date	04/02/2019

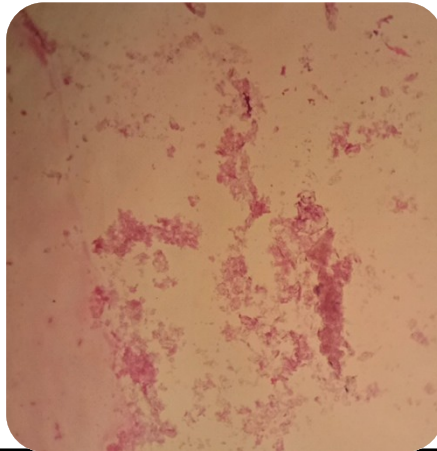
SURGICAL PATHOLOGY REPORT

Solitary calculus

DIAGNOSIS

Kindly co-relate clinically

Advice Stone analysis by spectrophotometry.



SPECIMEN

Solitary calculus

GROSS

Received tiny tissue piece.


Microscopy

1. Section examined shows irregular and rhombic shape crystal.

Note : All biopsy specimen will be stored for 15 (fifteen)days, block and slides for 5(five) years only from the time of receipt at the laboratory. No request ,for any of the above ,will be entertained after the due date.

Reference

- i) Rosai and Ackerman's Surgical Pathology.
- ii) Modern Surgical Pathology.



Gulshan Yadav, MD
Consultant Pathologist