

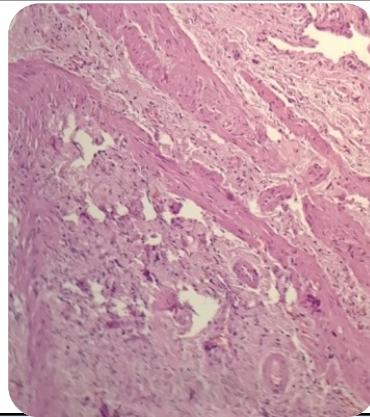
Patient Name	Mrs. HASSINA	Client Name	New Unique Diagnostic Centre	Specimen Received	27/01/2019
Age/Sex	35/F		Jammu & Kashmir	Specimen Type	Tissue
Patient ID	011901240339	Client Code	MolQ1518P	Collection Date	27/01/2019
Specimen ID	MOLQ/B-144/19	Ref. Doc	DR. ISHFAQ (HEALTH CRESEN	Report Date	29/01/2019

SURGICAL PATHOLOGY REPORT

GALL BLADDER.

DIAGNOSIS

CHOLECYSTITIS WITH CHOLELITHIASIS



SPECIMEN

Gall Bladder.

GROSS

Received 6.4x2.8cm long gall bladder. Cut section shows tiny stones.

Microscopy

- Section examined shows ulcerative mucosa and rokitansky aschoff sinus (irregularly shaped tubular structures lined by cuboidal lining epithelium with round to oval nucleus) with fibro collagenous tissue and inflammatory cells (lymphocytes).

Note : All biopsy specimen will be stored for 15 (fifteen) days, block and slides for 5 (five) years only from the time of receipt at the laboratory. No request ,for any of the above will be entertained after the due date.

Reference

- Rosai and Ackerman's Surgical Pathology.
- Modern Surgical Pathology.

Gulshan Yadav, MD
Consultant Pathologist