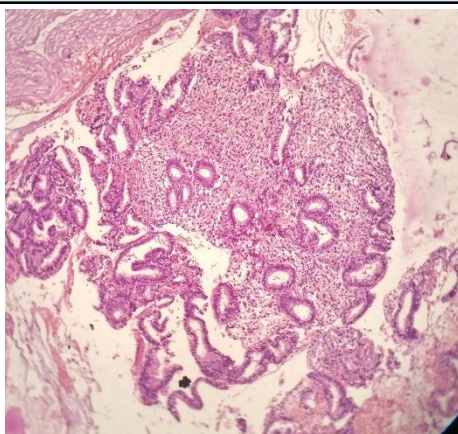


Patient Name	Mrs. SHUGUFTA	Client Name	Patients Care Clinical	Specimen Received	29-01-2019
Age/Sex	28/F		Laboratory, J and K	Specimen Type	Tissue
Patient ID	011901290104	Client Code	MolQ1839P	Collection Date	29-01-2019
Specimen ID	MOLQ/B-159/19	Ref. Doctor	DR SARA GDO	Report Date	01-02-2019

SURGICAL PATHOLOGY REPORT

ENDOMETRIUM

Proliferative phase



SPECIMEN

Endometrium

GROSS

Received multiple greyish white tissue piece.

Microscopy

1. Section examined shows small endometrial glands cuboidal lining epithelium having round nucleus stroma shows mononuclear inflammatory cells .
2. No granuloma and no malignant cells seen.

Note : All biopsy specimen will be stored for 15 (fifteen) days, block and slides for 5 (five) years only from the time of receipt at the laboratory. No request for any of the above, will be entertained after the due date.

Reference

- i) Rosai and Ackerman's Surgical Pathology.
- ii) Modern Surgical Pathology.

Gulshan Yadav, MD
Consultant Pathologist