

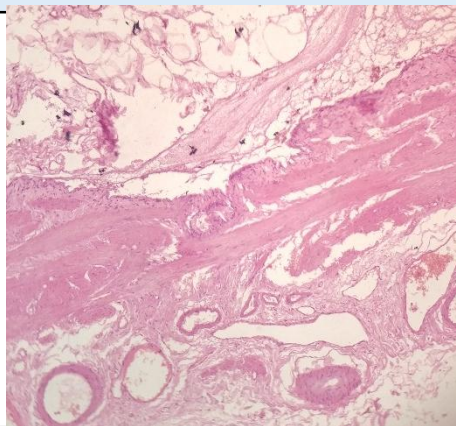
Patient Name	Mrs. ANGOORI DEVI	Client Name	Accurate Path (C), Agra	Specimen Received	29/01/2019
Age/Sex	42/F	Client Code	MolQ1671CM	Specimen Type	Tissue
Patient ID	011901290021	Ref. Doc	DR H V GUPTA	Collection Date	29/01/2019
Specimen ID	MOLQ/B-157/19			Report Date	01/02/2019

SURGICAL PATHOLOGY REPORT

GALL BLADDER.

DIAGNOSIS

CHOLECYSTITIS WITH CHOLELITHIASIS



SPECIMEN

Gall Bladder.

GROSS

Received 4.5x2.8cm long gall bladder. Cut section shows stones.

Microscopy

- Section examined shows ulcerative mucosa and Rokitansky-Aschoff sinuses (irregularly shaped tubular structures lined by cuboidal lining epithelium with round to oval nucleus) with fibrocollagenous tissue and inflammatory cells (lymphocytes).

Note : All biopsy specimen will be stored for 15 (fifteen) days, block and slides for 5 (five) years only from the time of receipt at the laboratory. No request for any of the above will be entertained after the due date.

Reference

- Rosai and Ackerman's Surgical Pathology.
- Modern Surgical Pathology.

Gulshan Yadav, MD
Consultant Pathologist