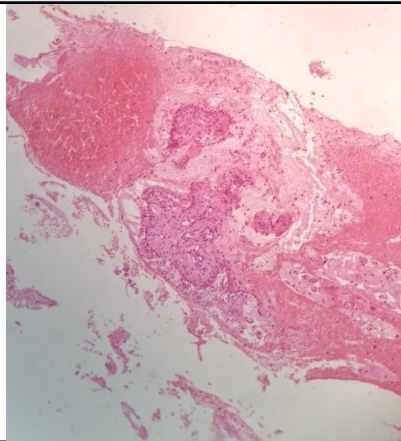


Patient Name	Mrs. JAIBA	Client Name	Asian Diagnostic Centre	Specimen Received	28/01/2019
Age/Sex	30 Years/Female	Client Code	MolQ1300CW	Specimen Type	Tissue
Patient ID	011901280169			Collection Date	28/01/2019
Specimen ID	MOLQ/B-151/19			Report Date	31/01/2019

SURGICAL PATHOLOGY REPORT

ENDOMETRIUM

KINDLY, CO-RELATE CLINICALLY.



SPECIMEN

Endometrium

GROSS

Received multiple greyish white tissue piece.

Microscopy

1. Section examined shows predominantly ectocervix lining having small round nucleus with occasional broken endometrial glands with cuboidal lining cells having small round nucleus.
2. No malignant cells and no granuloma seen in sample received.

Note : All biopsy specimen will be stored for 15 (fifteen) days, block and slides for 5 (five) years only from the time of receipt at the laboratory. No request for any of the above, will be entertained after the due date.

Reference

- i) Rosai and Ackerman's Surgical Pathology.
- ii) Modern Surgical Pathology.

**Gulshan Yadav, MD
Consultant Pathologist**