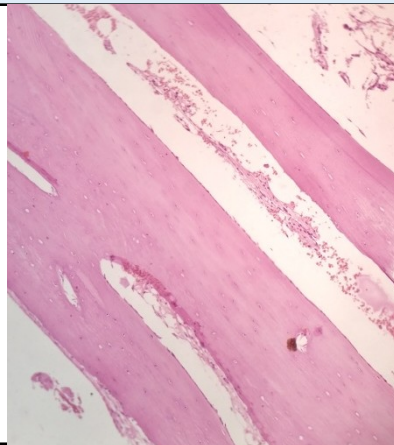


Patient Name	Master. RAM MILAN	Client Name	Brijanand Path Lab	Specimen Received	25/01/2019
Age/Sex	11 Years/Female	Client Code	MOLQ1133CM	Specimen Type	Tissue
Patient ID	011901250122			Collection Date	25/01/2019
Specimen ID	MOLQ/B-133/19			Report Date	31/01/2019

SURGICAL PATHOLOGY REPORT

Swelling Right Arm (Osteochondroma?)

BENIGN BONE FORMING LESION OSTEOID OSTEOMA?



SPECIMEN

Swelling Right Arm
(Osteochondroma?)

GROSS

Received 1.5x1cm bony tissue piece.

Microscopy

1. Section examined shows lamellar bone with osteocytes in lacunae and lined by osteoblasts, mature adipose cells.
2. No granuloma and no malignant cells seen.

Note : All biopsy specimen will be stored for 15 (fifteen) days, block and slides for 5 (five) years only from the time of receipt at the laboratory. No request for any of the above, will be entertained after the due date.

Reference

- i) Rosai and Ackerman's Surgical Pathology.
- ii) Modern Surgical Pathology.

Gulshan Yadav, MD
Consultant Pathologist