

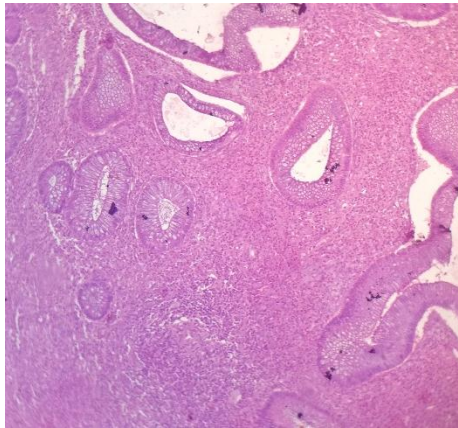
<b>Patient Name</b>	Master. SAHIL	<b>Client Name</b>	New Unique Diagnostic Center J & K	<b>Specimen Received</b>	27/01/2019
<b>Age/Sex</b>	05Years/Male	<b>Client Code</b>	MolQ1833P	<b>Specimen Type</b>	Tissue
<b>Patient ID</b>	011901240341	<b>Ref. Doctor</b>	DR. ISHFAQ (HEALTH CRESENT)	<b>Collection Date</b>	27/01/2019
<b>Specimen ID</b>	MOLQ/B-143/19			<b>Report Date</b>	30/01/2019

## SURGICAL PATHOLOGY REPORT

Rectal polyp

### DIAGNOSIS

**Inflammatory polyp.**



#### SPECIMEN

Rectal polyp

#### GROSS

Received two tissue piece 1x1cm and 2x2cm greyish white.

#### Microscopy

- Section examined shows sub mucosal glands having columnar lining epithelium with small round to oval nucleus with inflammatory cells( polymorphs, lymphocyte, plasmacytoid cells and eosinophils).

**Note :** All biopsy specimen will be stored for 15 (fifteen)days, block and slides for 5(five) years only from the time of receipt at the laboratory. No request ,for any of the above ,will be entertained after the due date.

#### Reference

- Rosai and Ackerman's Surgical Pathology.
- Modern Surgical Pathology. *Report generated at MolQ Laboratory, Gurgaon*

**Gulshan Yadav, MD**  
Consultant Pathologist