

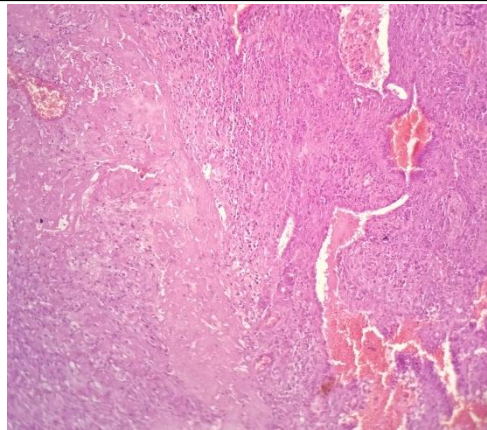
<b>Patient Name</b>	Mrs. ROSHINI	<b>Client Name</b>	Patients Care Clinical	<b>Specimen Received</b>	24/01/2019
<b>Age/Sex</b>	28 YRS/F		Laboratory, J & K	<b>Specimen Type</b>	Tissue
<b>Patient ID</b>	011901240288	<b>Client Code</b>	MolQ1839P	<b>Collection Date</b>	24/01/2019
<b>Specimen ID</b>	MOLQ/B-132/19	<b>Ref. Doctor</b>	OPD (S Z CLI LAB)	<b>Report Date</b>	30/01/2019

## SURGICAL PATHOLOGY REPORT

Molar pregnancy

### DIAGNOSIS

**PRODUCT OF CONCEPTION**



#### SPECIMEN

Molar pregnancy

#### GROSS

Received multiple greyish white tissue piece.

#### Microscopy

- Section examined shows small endometrial glands having small round nucleus, decidual cells with few trophoblastic cells, no hydrophobic changes seen in the sample received.

**Note :** All biopsy specimen will be stored for 15 (fifteen)days, block and slides for 5(five) years only from the time of receipt at the laboratory. No request ,for any of the above ,will be entertained after the due date.

#### Reference

- Rosai and Ackerman's Surgical Pathology.
- Modern Surgical Pathology. *Report generated at MolQ Laboratory, Gurgaon*

**Gulshan Yadav, MD**  
**Consultant Pathologist**