

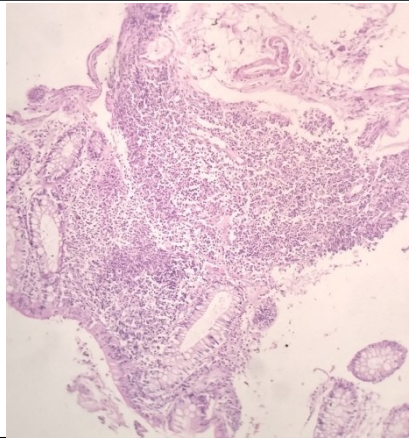
<b>Patient Name</b>	<b>Mr. SATYA PAL</b>	<b>Client Name</b>	Sunrise Diagnostic Centre,	<b>Specimen Received</b>	27-Jan-2019
<b>Age/Sex</b>	58/Male		Agra	<b>Specimen Type</b>	Tissue
<b>Patient ID</b>	011901270016	<b>Client Code</b>	MolQ1358CM	<b>Collection Date</b>	27-Jan-2019
<b>Specimen ID</b>	MOLQ/B-139/19	<b>Ref. Doctor</b>		<b>Report Date</b>	28-Jan-2019

## SURGICAL PATHOLOGY REPORT

Prolapsed Hemorrhoids with colonic ulcers (? Nature)

### DIAGNOSIS

**CHRONIC NON-SPECIFIC INFLAMMATION**



#### SPECIMEN

Prolapsed Hemorrhoids with colonic ulcers  
(? Nature)

#### GROSSING

Received 1 slide for review.

#### Microscopy

1. Section examined shows mucosal lining epithelium with attenuation of villi having round to oval nucleus. Deeper tissue shows sub mucosal glands with inflammatory cells.
2. Section also shows a bit of tissue with mononuclear inflammatory cells and histiocytes.
3. No malignant cell seen.
4. No well formed granuloma seen.
5. No cryptic abscess seen.

**Note :** All biopsy specimen will be stored for 15 (fifteen) days, block and slides for 5 (five) years only from the time of receipt at the laboratory. No request for any of the above will be entertained after the due date.

#### Reference

- i) Rosai and Ackerman's Surgical Pathology.
- ii) Modern Surgical Pathology

**Gulshan Yadav, MD**  
Consultant Pathologist