

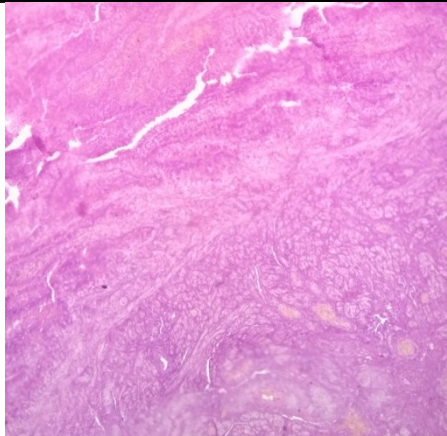
<b>Patient Name</b>	<b>Mr. AKLESH KUMAR</b>	<b>Client Name</b>	Kamal Hospital and	<b>Specimen Received</b>	23/01/2019
<b>Age/Sex</b>	30 Years/Male		Maternity Centre	<b>Specimen Type</b>	Tissue
<b>Patient ID</b>	011901230179	<b>Client Code</b>	MolQ1329CM	<b>Collection Date</b>	23/01/2018
<b>Specimen ID</b>	MOLQ/B-126/19	<b>Ref. Doctor</b>		<b>Report Date</b>	25/01/2018

## SURGICAL PATHOLOGY REPORT

### APPENDIX.

#### DIAGNOSIS

**ACUTE APPENDICITIS**



#### SPECIMEN

Appendix.

#### GROSS

Received 4x1.2cm long appendix. Cut section shows fecalith.

#### Microscopy

- Section examined shows lymphoid follicles with ulcerative mucosa. Deeper tissue shows inflammatory cells (polymorphs, lymphocytes and few histiocytes).

**Note :** All biopsy specimen will be stored for 15 (fifteen)days, block and slides for 5(five) years only from the time of receipt at the laboratory. No request ,for any of the above ,will be entertained after the due date.

#### Reference

- Rosai and Ackerman's Surgical Pathology.
- Modern Surgical Pathology.

**Gulshan Yadav, MD**  
Consultant Pathologist