

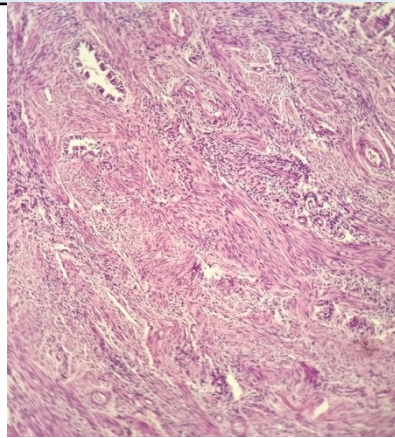
<b>Patient Name</b>	Mrs. DOLLY	<b>Client Name</b>	C/O NEW MAYUR HOSPITAL(AGRA)	<b>Specimen Received</b>	24/01/2019
<b>Age/Sex</b>	27 YRS/F	<b>Client Code</b>		<b>Specimen Type</b>	Tissue
<b>Patient ID</b>	011901240002	<b>Ref. Doctor</b>		<b>Collection Date</b>	24/01/2019
<b>Specimen ID</b>	MOLQ/B-130/19			<b>Report Date</b>	25/01/2019

## SURGICAL PATHOLOGY REPORT

Uterus

### DIAGNOSIS

**Chronic Cervicitis with Hemorrhagic Cyst.**



#### SPECIMEN

Uterus

#### GROSS

Received 10.5x5.2cm long uterus with cervix with bilateral adnexa.  
Ovary measuring 5x3.2cm, 5x2cm uniloculated cyst with straw colour fluid.

#### Microscopy

Section examined shows

1. Endometrium with proliferative phase.
2. Myometrium with mononuclear inflammatory cells.
3. Ovary shows haemorrhagic cyst and tube unremarkable.
4. Other ovary and tube unremarkable.

**Note :** All biopsy specimen will be stored for 15 (fifteen) days, block and slides for 5 (five) years only from the time of receipt at the laboratory. No request, for any of the above, will be entertained after the due date.

**Gulshan Yadav, MD**  
Consultant Pathologist

#### Reference

- i) Rosai and Ackerman's Surgical Pathology.
- ii) Modern Surgical Pathology. *Report generated at MolQ Laboratory, Gurgaon*