

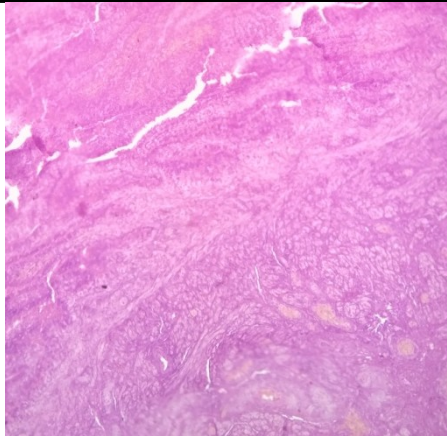
<b>Patient Name</b>	<b>Mr. AKLESH KUMAR</b>	<b>Client Name</b>	Kamal Hospital and	<b>Specimen Received</b>	23/01/2019
<b>Age/Sex</b>	30 Years/Male		Maternity Centre	<b>Specimen Type</b>	Tissue
<b>Patient ID</b>	011901230179	<b>Client Code</b>	MolQ1329CM	<b>Collection Date</b>	23/01/2018
<b>Specimen ID</b>	MOLQ/B-126/19	<b>Ref. Doctor</b>		<b>Report Date</b>	25/01/2018

## SURGICAL PATHOLOGY REPORT

### APPENDIX.

#### DIAGNOSIS

**ACUTE ON CHRONIC APPENDICITIS**



#### SPECIMEN

Appendix.

#### GROSS

Received 4x1.2cm long appendix. Cut section shows fecalith.

#### Microscopy

- Section examined shows lymphoid follicles with ulcerative mucosa. Deeper tissue shows inflammatory cells (polymorphs, lymphocytes and few histiocytes).

**Note :** All biopsy specimen will be stored for 15 (fifteen) days, block and slides for 5 (five) years only from the time of receipt at the laboratory. No request, for any of the above, will be entertained after the due date.

#### Reference

- Rosai and Ackerman's Surgical Pathology.
- Modern Surgical Pathology.

**Gulshan Yadav, MD**  
Consultant Pathologist