

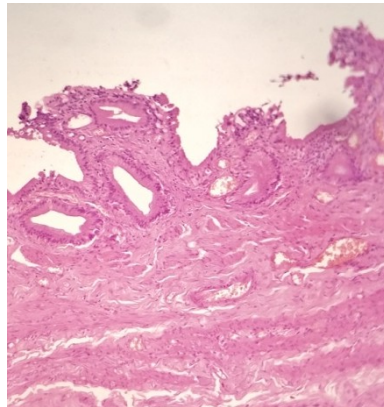
Patient Name	Mrs. PREETI	Client Name	Arban Hospital,	Specimen Received	23/01/2019
Age/Sex	20 Years/Female		Nuh	Specimen Type	Tissue
Patient ID	011901230122	Client Code	MolQ1684P	Collection Date	23/01/2019
Specimen ID	MOLQ/B-124/19	Ref. Doctor		Report Date	25/01/2019

SURGICAL PATHOLOGY REPORT

GALL BLADDER.

DIAGNOSIS

CHOLECYSTITIS WITH CHOLELITHIASIS



SPECIMEN

Gall Bladder.

GROSS

Received 6.4x3.1cm long gall bladder. Cut section shows stones.

Microscopy

- Section examined shows ulcerative mucosa and Rokitansky Aschoff sinus (irregularly shaped tubular structures lined by cuboidal lining epithelium with round to oval nucleus) with fibro collagenous tissue and inflammatory cells (lymphocytes).

Note : All biopsy specimen will be stored for 15 (fifteen) days, block and slides for 5 (five) years only from the time of receipt at the laboratory. No request for any of the above will be entertained after the due date.

Reference

- Rosai and Ackerman's Surgical Pathology.
- Modern Surgical Pathology.

Gulshan Yadav, MD
Consultant Pathologist