

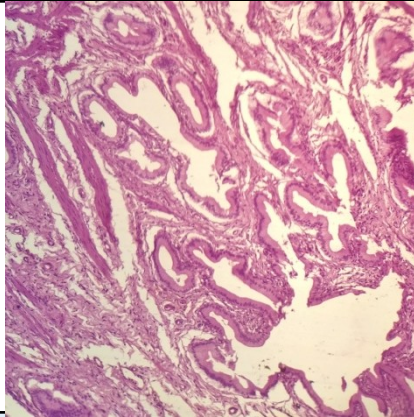
Patient Name	Mrs. ROZY	Client Name	New Unique Diagnostic Center,	Specimen Received	22/01/2019
Age/Sex	30 Years/Female		Jammu & Kashmir	Specimen Type	Tissue
Patient ID	011901220335	Client Code	MolQ1833P	Collection Date	22/01/2019
Specimen ID	MOLQ/B-122/19	Ref. Doctor	LIFE CARE DOORU	Report Date	24/01/2019

SURGICAL PATHOLOGY REPORT

GALL BLADDER.

DIAGNOSIS

CHOLECYSTITIS WITH CHOLELITHIASIS



SPECIMEN

Gall Bladder.

GROSS

Received 6.5x3.1cm long gal bladder cut section shows tiny stones.

Microscopy

- Section examined shows ulcerative mucosa and Rokitansky Aschoff sinus (irregularly shaped tubular structures lined by cuboidal lining epithelium with round to oval nucleus) with fibro collagenous tissue and inflammatory cells (lymphocytes).

Note : All biopsy specimen will be stored for 15 (fifteen) days, block and slides for 5 (five) years only from the time of receipt at the laboratory. No request ,for any of the above ,will be entertained after the due date.

Reference

- Rosai and Ackerman's Surgical Pathology.
- Modern Surgical Pathology.

Gulshan Yadav, MD
Consultant Pathologist