

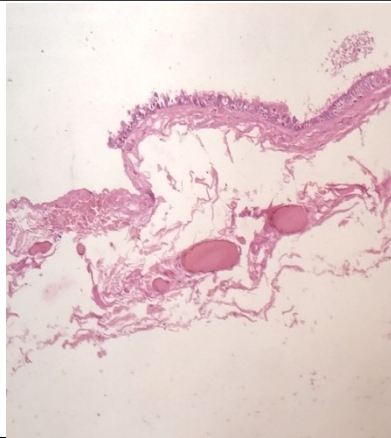
Patient Name	Mr. RAKESH	Client Name	Arban Hospital,	Specimen Received	19-Jan-2019
Age/Sex	35/Male		Nuh	Specimen Type	Tissue
Patient ID	011901190224	Client Code	MolQ1684P	Collection Date	19-Jan-2019
Specimen ID	MOLQ/B-105/19	Ref. Doctor		Report Date	24-Jan-2019

SURGICAL PATHOLOGY REPORT

Scrotal Swelling (Cyst)

DIAGNOSIS

DERMAL NEVUS WITH MILD ATYPIA



SPECIMEN

Scrotal Swelling (Cyst)

GROSSING

Received 2x2 cm cystic tissue pieces. Cut section shows straw colored fluid.

Microscopy

- Section examined shows single cuboidal lining epithelium with round to oval nucleus. Lumen shows mature sperms. Fibrocollagenous tissue and inflammatory cells. No granuloma and no malignant cells seen.

Note : All biopsy specimen will be stored for 15 (fifteen) days, block and slides for 5 (five) years only from the time of receipt at the laboratory. No request for any of the above will be entertained after the due date.

Reference

- Rosai and Ackerman's Surgical Pathology.
- Modern Surgical Pathology

Gulshan Yadav, MD
Consultant Pathologist