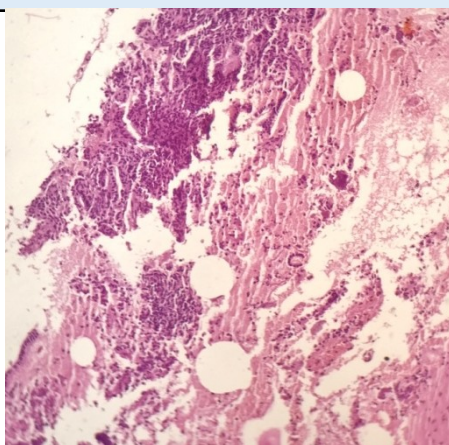


Patient Name	Mrs. KAVITA	Client Name	Asian Diagnostic Centre	Specimen Received	21/01/2019
Age/Sex	22 Years/Female	Client Code	MolQ1300CW	Specimen Type	Tissue
Patient ID	011901210167			Collection Date	21/01/2019
Specimen ID	MOLQ/B-116/19			Report Date	23/01/2019

SURGICAL PATHOLOGY REPORT

ENDOMETRIUM

PROLIFERATIVE PHASE



SPECIMEN

Endometrium

GROSS

Received multiple greyish white tissue piece.

Microscopy

1. Section examined shows scanty tissue with few broken endometrial glands having small cuboidal lining epithelium small round nucleus with bit of endocervical and ectocervix.
2. No granuloma and no malignant cells seen.

Note : All biopsy specimen will be stored for 15 (fifteen) days, block and slides for 5 (five) years only from the time of receipt at the laboratory. No request for any of the above, will be entertained after the due date.

Reference

- i) Rosai and Ackerman's Surgical Pathology.
- ii) Modern Surgical Pathology.

Gulshan Yadav, MD
Consultant Pathologist