

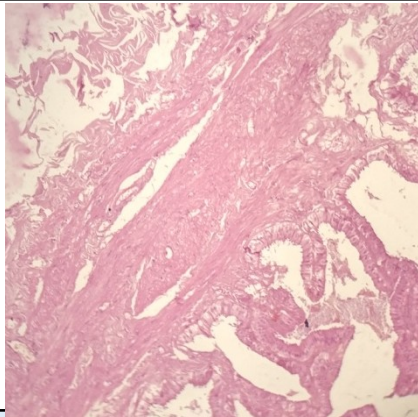
Patient Name	Mrs. ASIFA SALOOK	Client Name	Tantray Labs, Jammu & Kashmir	Specimen Received	20/01/2019
Age/Sex	35 Years/Female	Client Code	MolQ1849P	Specimen Type	Tissue
Patient ID	011901200198	Ref. Doctor	WANI LAB GBL	Collection Date	20/01/2019
Specimen ID	MOLQ/B-110/19			Report Date	23/01/2019

SURGICAL PATHOLOGY REPORT

GALL BLADDER.

DIAGNOSIS

CHOLECYSTITIS WITH CHOLELITHIASIS



SPECIMEN

Gall Bladder.

GROSS

Received 6.5x2.2cm long gall bladder. Cut section shows stone .

Microscopy

- Section examined shows ulcerative mucosa and rokitansky aschoff sinus (irregularly shaped tubular structures lined by cuboidal lining epithelium with round to oval nucleus) with fibro collagenous tissue and inflammatory cells (lymphocytes).

Note : All biopsy specimen will be stored for 15 (fifteen)days, block and slides for 5(five) years only from the time of receipt at the laboratory. No request ,for any of the above ,will be entertained after the due date.

Reference

- Rosai and Ackerman's Surgical Pathology.
- Modern Surgical Pathology.

Gulshan Yadav, MD
Consultant Pathologist